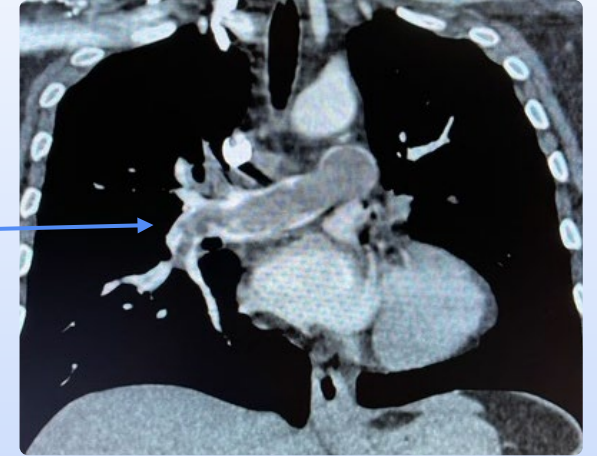

Pulmonary Arterial Thrombectomy Case Example

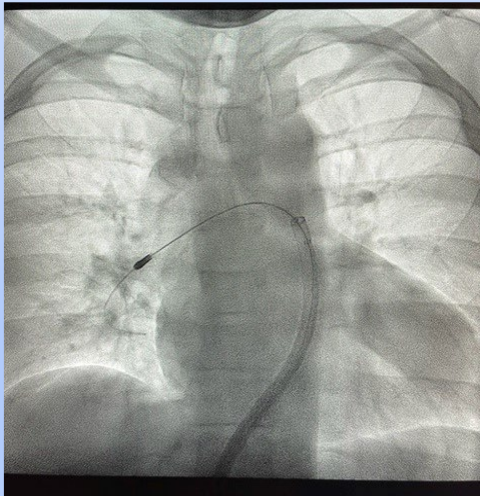
Clinical presentation:

- Middle-aged female with shortness of breath who “passed out” at home
- In ER, requiring oxygen with normal blood pressure but elevated heart rate
- CT scan with large central clot burden
- Lab studies demonstrated strain on the right heart
- Pulmonary Embolism Response Team Conference Decision: Pulmonary Arterial Thrombectomy with Inari FlowTrievers



Pre-procedure CT Scan

Inari FlowTrievers Removing Embolism



Embolism/blood clot removed



- Excellent results with Inari FlowTrievers
- Pulmonary artery pressure normalized and flow restored to normal
- Patient no longer required oxygen
- Discharged within 48 hours without complication

Post thrombectomy demonstrating excellent flow.

